Original research

Emergent microsurgical intervention for acute stroke after mechanical thrombectomy failure: a prospective study

Jiří Fiedler ,[1,2] Martin Roubec ,[3,4] Marek Grubhoffer,[1,2] Svatopluk Ostrý ,[5,6] Václav Procházka ,[7] Kateřina Langová,[8] David Školoudík ,[4,7] for the EMIAS Study Group

► Additional supplemental material is published online only. To view, please visit the journal online (http://dx.doi. org/10.1136/neurintsurg-2022-018643).

For numbered affiliations see end of article.

Correspondence to
Professor David Školoudík, Center for Health Research, University of Ostrava Faculty of Medicine, Ostrava, Czech Republic; skoloudik@hotmail.com

JříF and MR contributed equally.

Received 3 January 2022
Accepted 3 April 2022

ABSTRACT

Background Despite all the gains that have been achieved with endovascular mechanical thrombectomy revascularization and intravenous thrombolysis logistics since 2015, there is still a subgroup of patients with salvageable brain tissue for whom persistent emergent large vessel occlusion portends a catastrophic outcome.

Objective To test the safety and efficacy of emergent microsurgical intervention in patients with acute ischemic stroke and symptomatic middle cerebral artery occlusion after failure of mechanical thrombectomy.

Methods A prospective two-center cohort study was conducted. Patients with acute ischemic stroke and middle cerebral artery occlusion for whom recanalization failed at center 1 were randomly allocated to the microsurgical intervention group (MSIG) or control group 1 (CG1). All similar patients at center 2 were included in the control group 2 (CG2) with no surgical intervention. Microsurgical embolectomy and/or extracranial–intracranial bypass was performed in all MSIG patients at center 1.

Results A total of 47 patients were enrolled in the study: 22 at center 1 (12 allocated to the MSIG and 10 to the CG1) and 25 patients at center 2 (CG2). MSIG group patients showed a better clinical outcome on day 90 after the stroke, where a modified Rankin Scale score of 0–2 was reached in 7 (58.3%) of 12 patients compared with 1/10 (10.0%) patients in the CG1 and 3/12 (12.0%) in the CG2.

Conclusions This study demonstrated the potential for existing microsurgical techniques to provide good outcomes in 58% of microsurgically treated patients as a third-tier option.

Key messages

What is already known?

► Recanalization of the cerebral artery using intravenous thrombolysis or mechanical thrombectomy is the only effective treatment, regardless of intervention, for ischemic stroke within the standard time window or in cases with favorable perfusion mismatch even beyond it. On the contrary, persisting occlusion is a predictor of an unsatisfactory clinical outcome. The microsurgical techniques comprising extracranial–intracranial bypass and microsurgical embolectomy have been used for large cerebral vessel recanalization for nearly 50 years.

What this study adds?

► This two-center study has shown in a small number of patients that emergency microsurgery can provide a good clinical outcome (modified Rankin Scale score 1 and 2) in 58% of patients with middle cerebral artery occlusion and a subsequent standard recanalization therapy failure.

How this study might affect research, practice, or policy?

► When used at experienced medical centers by microvascular neurosurgeons, microsurgery should be systematically evaluated as an urgent management in cases with standard treatment failure.

Check for updates

© Author(s) (or their employer(s)) 2022. No commercial re-use. See rights and permissions. Published by BMJ.

To cite: Fiedler J, Roubec M, Grubhoffer M, *et al*. *J NeuroIntervent Surg* Epub ahead of print: [*please include* Day Month Year]. doi:10.1136/neurintsurg-2022-018643

INTRODUCTION

Endovascular techniques and equipment are continuously undergoing improvements since the revolutionary introduction of mechanical thrombectomy (MT). MT has became integral to the standard-of-care treatment for patients with acute ischemic stroke (AIS) with emergent large vessel occlusion (ELVO) in 2015.[1] However, recanalization is still not reached in 11–29% of patients, with a final thrombolysis in cerebral infarction (TICI) score of 0–1 after MT.[2]

Intracranial stenting might be an option when MT fails. Prior studies have indicated that direct intracranial percutaneous balloon angioplasty with stenting can reach high recanalization rates.[3] However, there are still up to 30% of patients with MT failure in whom recanalization is not reached with rescue intervention.[4 5] Thus 3–9% of patients are expected to fail reaching recanalization with endovascular approaches depending on the center experience. Persistent ELVO is a predictor of poor clinical outcome.[6]

Microsurgical intervention (MSI) might offer another method for ELVO recanalization in the anterior circulation using two main approaches or their combination: the first, a direct vessel recanalization with microsurgical embolectomy (MSE), and the

J NeuroIntervent Surg: first published as 10.1136/neurintsurg-2022-018643 on 15 April 2022. Downloaded from http://jnis.bmj.com/ on April 20, 2022 at Cambridge University Library. Protected by copyright.

second using an extracranial–intracranial (EC–IC) bypass.[7 8] The advantage of MSE lies in its potential for recanalizing the perforators in cases where they branch from the occluded segment, with the sphenoidal part of the middle cerebral artery (MCA) being an example. The first MSE was performed by Jacobson and Donaghy in 1962.[9] In other studies with small samples of patients treated with MSE only, the recanalization rate reached 91–100%.[10 11]

The second revascularization option is the EC–IC bypass, which was first performed by Woringer and Kunlin in the case of an internal carotid artery (ICA) occlusion in 1962 and then by Yaşargil in the case of MCA occlusion in 1967.[9] The superficial temporal artery (STA) acts as a donor providing blood flow to the MCA trunks or segments distal to the occlusion site, with the cause of the blockage left in situ. The benefit of the EC–IC bypass in prevention of secondary stroke has not yet been demonstrated.[12] The EC–IC bypass is potentially suitable in cases of pronounced intracranial atherosclerosis where MSE failure is expected.[8] Thus, the surgeon should be prepared for the eventuality of using both MSE and EC–IC bypass during an urgent surgery.

The present study aimed to assess the safety and efficacy of emergency MSI (MSE and/or EC–IC bypass) in patients with AIS with symptomatic MCA occlusion with or without intracranial ICA occlusion and intravenous thrombolysis (IVT) and/or MT failure.

METHODS

Ethical declaration

The entire study was conducted in accordance with the Helsinki Declaration of 1975 (as revised in 1983 and 2008). The study protocol was created using systemic review data from the register (registration number PROSPERO: CRD42017078511). The study protocol (ClinicalTrials ID: NCT05153642) with a reference No. 109/17 was approved by the ethics committee of the České Budějovice Hospital. All patients or a family representative signed the informed consent form.

Patients

A prospective two-center case–control study was conducted with randomized allocation to the study procedure. We included between January 2016 and December 2020, all consecutive patients with AIS who presented with acute symptomatic occlusion of the MCA (in the M1 or M2 segment) with or without intracranial ICA occlusion and for whom recanalization by MT (with or without IVT) failed at the comprehensive stroke center of the České Budějovice Hospital and the comprehensive stroke center of the University Hospital Ostrava.

The inclusion criteria were as follows: (1) age ≥18 years; (2) indication for MT according to valid guidelines[13]; (3) modified Rankin Scale (mRS) score ≤2 before stroke onset; (4) baseline Alberta Stroke Program Early CT Score (ASPECTS) ≥6; (5) MCA occlusion in the M1 or M2 segment with or without intracranial ICA occlusion; (6) MT failure with TICI score of 0–1 declared by an interventional neuroradiologist; and (7) time onset-to-recanalization (IVT and/or MT) failure ≤6 hour or core/penumbra mismatch in cases with wake-up stroke or stroke with an unknown onset.

Exclusion criteria were as follows: (1) indication for MT according to valid guidelines;[13] (2) thrombocyte count ≤100 000/µL; and (3) contraindication for general anesthesia.

Patients after MT failure at the first comprehensive stroke center (center 1) were randomly allocated to the microsurgical intervention group (MSIG) or standard of care control group 1 (CG1). All consecutive patients with standard stroke care and recanalization failure after MT without any subsequent surgical interventions at the second comprehensive stroke center (center 2) were included in the control group 2 (CG2) to support reproducibility and eliminate bias in patient selection for MSI.

Demographics (age, sex) and medical history (arterial hypertension; diabetes mellitus; hyperlipidemia; body mass index; previous stroke or transient ischemic attack; ischemic heart disease; atrial fibrillation; smoking; alcohol abuse; previous use of antithrombotics, anticoagulants, and statins; glucose and cholesterol level at admission; and blood pressure at admission) data were collected in all patients at admission. The neurological status was assessed using the National Institutes of Health Stroke Scale (NIHSS) score at admission, at 24 hours, and at 7 days after stroke onset. Collected data for clinical outcomes included mRS score at 90 days after stroke onset, 7-day and 90-day mortality, and incidence of symptomatic intracerebral hemorrhage (sICH). sICH was defined as type 2 parenchymal hematoma and clinical worsening with an NIHSS score ≥4.[14] Favorable clinical outcome was defined as an mRS score of 0–2 on day 90 after stroke onset.

IVT and MT treatment

Both the stroke centers involved in the study have been managing patients with acute stroke for at least 15 years, with a high number of IVT (more than 100 per year) and MT (more than 80 per year) cases complying with local or European Stroke Organization certification regulations. The IVT and MT treatment protocols followed at both the centers were in accordance with the current practice recommendations by the American Heart Association/American Stroke Association,[13] European Stroke Organization[15 16] throughout the study. All patients were examined using CT and CT angiography on admission. Patients with wake-up stroke or unknown stroke onset were also examined using CT perfusion mismatch scans or magnetic resonance diffusion-weighted images/fluid-attenuated inversion recovery mismatch to evaluate ischemic core and penumbra for treatment indication according to the above-mentioned guidelines.

The following stroke data and logistical information were collected in all patients: occlusion location, occlusion side, stroke etiology, early ischemic changes evaluated using ASPECTS, onset-to-admission time, onset-to-needle time for IVT, onset-to-groin time for MT, and final TICI score.

MT failure declaration

The MT procedure was always indicated by a stroke physician and performed by an experienced interventional neuroradiologist with expertise in cerebral vessel evaluation and treatment techniques. MT recanalization success was assessed using the TICI scale.[17] Cases with TICI scores of 0 and 1 were evaluated as recanalization failure. Recanalization failure was declared after at least three unsuccessful attempts to retrieve the thrombi using a retrieval or aspiration tool, or after failure to reach the site of occlusion using the guiding wire. The declaration of onset-to-failure time has been assessed in all cases.

Microsurgical intervention

Study protocol

A protocol for emergent microsurgical treatment as a rescue therapy for cases with MT failure as a third-tier option was established and approved by the local ethical committee. The need for

J NeuroIntervent Surg: first published as 10.1136/neurintsurg-2022-018643 on 15 April 2022. Downloaded from http://jnis.bmj.com/ on April 20, 2022 at Cambridge University Library. Protected by copyright.

recanalization was always indicated by a stroke physician after MT failure was declared by an interventional neuroradiologist.

The request for MSI was reported to the surgeon immediately after encountering the first difficulties in reaching the occlusion site or a failure to resolve vessel obturation. Thus, the surgeon and the operating room were prepared for the MSI in advance, and the patient could be immediately transported after MT failure was declared.

Microsurgery technique and its prerequisites

All MSIs were performed by only one vascular neurosurgeon with experience of more than 200 EC–IC bypasses. In all patients we followed the 'time is brain' paradigm and the microsurgical intervention was performed without a time delay.

When intracranial atherosclerosis was detected in the preoperative images, the surgeon started the treatment with STA dissection. STA is a readily available donor for an EC–IC bypass, and its quality can be evaluated from the preoperative CT scan. The surgical approach varied depending on the position of the MCA bifurcation, occlusion site, and the depth of the sylvian fissure: lateral supraorbital craniotomy, or pterional craniotomy, or eyebrow incision.[18] The M1 and M2 segments of the MCA were thoroughly inspected. Whenever feasible, MSE was performed in an occluded vessel. Transverse arteriotomy was used in all cases of M1 terminus occlusion. Similarly, in cases of M2 occlusion, either transverse or longitudinal arteriotomy was performed after analyzing the patient's internal physical condition. The goal was to restore flow at the occlusion site and also at other sites distal to the site of occlusion, for facilitating lenticulostriate perforator reperfusion. EC–IC bypass was performed in cases when the flow after embolectomy was unsatisfactory.[19] Transit time flow measurement and indocyanine green angiography were performed to verify perforator patency and vessel flow during the procedures.

General anesthesia was administered by a dedicated anesthetist. Any hypotension episodes were carefully avoided after the introduction of general anesthesia.

Fibrinogen levels were checked at least 1 hour after IVT administration to predict early fibrinogen degradation coagulopathy and to lower the procedural and postprocedural risk of bleeding.[20] Fibrinogen was supplemented with Haemocomplettan P (CSL Behring GmbH, Marburg, Germany) in cases with levels of <1 g/L. The fibrinogen level was checked again on skin closure and then the following day 24 hours after IVT. In patients with no antiplatelet drug history prior to stroke, 500 mg of intravenous acetylsalicylic acid were administered during the revascularization procedure.

Statistical analysis

The sample size was based on an expected 50% difference in the percentage of patients with a favorable clinical outcome (mRS score 0–2) between microsurgical and control groups. Pre-study calculation showed that it was necessary to enroll a minimum of 22 patients to reach a statistically significant difference with an α value of 0.05 (two-tailed) and β value of 0.8.

The quantitative data were expressed as median, minimal, and maximal values. Categorical variables were described using absolute and relative frequencies. Non-parametric statistical methods were used because samples were too small to assess their true distribution. Differences between two independent groups were analyzed using the Mann-Whitney U test or Fisher's exact test. Bonferroni correction was used for multiple testing.

A p value of <0.05 was adopted to indicate the level of statistical significance. All statistical analyses were conducted with

Table 1 Patients' demographics and medical history

	MSIG (n=12)	CG1 (n=10)	P value	CG2 (n=25)	P value
Male sex; n (%)	6 (50.0)	4 (40.0)	0.970*	10 (40.0)	1.000*
Age; median (range)	75 (65–86)	79 (61–87)	0.469†	79 (60–90)	0.831†
Arterial hypertension; n (%)	11 (91.7)	9 (90.0)	1.000*	23 (92.0)	1.000*
Diabetes mellitus; n (%)	5 (41.7)	3 (30.0)	1.000*	2 (8.0)	0.051*
Hyperlipidemia; n (%)	5 (41.7)	4 (40.0)	1.000*	11 (44.0)	1.000*
Body mass index; median (IQR)	31.4 (26.3–36.4)	25.1 (20.8–34.0)	0.009†	27.0 (23.9–37.0)	0.017†
Stroke or TIA; n (%)	2 (16.7)	2 (20.0)	1.000*	5 (20.0)	1.000*
Coronary heart disease; n (%)	4 (33.3)	3 (30.0)	1.000*	9 (36.0)	1.000*
Atrial fibrillation; n (%)	7 (58.3)	6 (60.0)	1.000*	11 (44.0)	0.990*
Smoking; n (%)	1 (8.3)	3 (30.0)	0.589*	3 (12.0)	1.000*
Alcohol abuse; n (%)	0 (0.0)	0 (0.0)	1.000*	0 (0.0)	1.000*
Antithrombotics at admission; n (%)	7 (58.3)	8 (80.0)	0.762*	12 (48.0)	1.000*
Antiplatelets; n (%)	1 (8.3)	6 (60.0)	0.040*	9 (36.0)	0.238*
Anticoagulants; n (%)	6 (50.0)	2 (20.0)	0.408*	3 (12.0)	0.072*
Statins at admission; n (%)	4 (33.3)	3 (30.0)	1.000*	11 (44.0)	1.000*
Glycemia level at admission; median (IQR)	7.6 (5.1–11.4)	6.4 (5.5–11.3)	0.510†	7.3 (5.0–15.9)	1.000†
Cholesterol level at admission; median (IQR)	4.6 (3.0–5.6)	4.0 (3.4–5.6)	1.000†	4.1 (3.2–5.6)	1.000†
Systolic blood pressure at admission; median (IQR)	150 (110–200)	145 (116–210)	1.000†	150 (100–210)	1.000†
Diastolic blood pressure at admission; median (IQR)	80 (70–120)	80 (70–115)	0.941†	80 (55–110)	0.865†

*Fisher's exact test;
†Mann-Whitney U-test;
CG1, control group in center 1; CG2, control group in center 2; MSIG, microsurgical intervention group; TIA, transient ischemic attack.

J NeuroIntervent Surg: first published as 10.1136/neurintsurg-2022-018643 on 15 April 2022. Downloaded from http://jnis.bmj.com/ on April 20, 2022 at Cambridge University Library. Protected by copyright.

Table 2 Stroke and logistic data

	MSIG (n=12)	CG1 (n=10)	P value	CG2 (n=25)	P value
Location of arterial occlusion					
M1-MCA; n (%)	5 (41.7)	4 (40.0)	1.000*	18 (72.0)	0.292*
M2-MCA; n (%)	5 (41.7)	3 (30.0)	1.000*	6 (24.0)	0.886*
ICA +M1 MCA; n (%)	2 (16.7)	3 (30.0)	1.000*	1 (4.0)	0.482*
Right-side stroke; n (%)	7 (58.3)	7 (70.0)	1.000*	17 (68.0)	1.000*
Stroke etiology; n (%)					
Cardioembolic; n (%)	8 (66.7)	7 (70.0)	1.000*	14 (56.0)	1.000*
ICAS; n (%)	3 (25)	0 (0.0)	0.442*	9 (36.0)	1.000*
ESUS; n (%)	1 (8.3)	3 (30.0)	0.586*	1 (4.0)	1.000*
Dissection; n (%)	0.0	0 (0.0)	1.000	1 (4.0)	1.000*
ASPECT score; median (IQR)	9.5 (8–10)	8.5 (8–10)	1.000†	9.0 (6–10)	0.277†
Time onset-to-admission; median (IQR); min	93.0 (80–115)	85.0 (37–203)	1.000†	70.0 (20–230)	0.048†
IVT; n (%)	7 (58.3)	10 (100.0)	0.080*	25 (100.0)	0.004*
Time onset-to-needle; median (IQR); min	125.0 (101–165)	126.0 (65–210)	0.728†	105.0 (75–270)	0.056†
Time onset-to-groin; median (IQR); min	168.0 (135–270)	140.0 (120–210)	0.724†	160.0 (110–290)	0.761†
Time onset-to-recanalization failure; median (IQR); min	205.0 (125–360)	193.5 (125–270)	1.000†	210.0 (165–360)	1.000†
TICI 0 at time of recanalization failure; n (%)	11 (91.7)	9 (90.0)	1.000*	17 (68.0)	0.440*
TICI 1 at time of recanalization failure; n (%)	1 (8.3)	1 (10.0)	1.000*	8 (32.0)	0.440*

*Fisher's exact test;
†Mann-Whitney U-test;
ASPECT, Alberta Stroke Program Early CT; CG1, control group in center 1; CG2, control group in center 2; ESUS, embolic stroke of unknown source; ICA, internal carotid artery; ICAS, intracranial atherosclerosis; IVT, Intravenous thrombolysis; MCA, middle cerebral artery; MSIG, microsurgical inrtervention group; TICI, thrombolysis in cerebral infarction.

IBM SPSS Statistics for Windows, version 23.0 (IBM Corp., Armonk, New York, USA).

RESULTS

A total of 1482 patients with acute stroke underwent IVT and 484 had an MT procedure at center 1, and 693 patients with acute stroke underwent IVT and 637 had an MT procedure at center 2 during the 60-month study period. Of those, all 22 subsequent patients (4.5%) after a failed MT were enrolled at center 1. Twelve patients were randomly allocated to the MSIG (six men, mean age 75.3±6.1 years) and 10 patients to the CG1 (four men, mean age: 78.4±7.5 years). All 25 subsequent patients (4.3%) for whom recanalization after MT failed were enrolled at center 2 to the CG2 (ten men, mean age: 76.8±7.5 years).

None of the three groups had significant differences in the medical histories or baseline characteristics. However, the number of patients using anticoagulants was higher in the MSIG than in the control groups (50.0% vs 20.0% in CG1 and 12.0% in CG2) table 1, which explains the lower rate of IVT in the MSIC. All patients in both control groups (CG1 and CG2) underwent IVT prior to the MT attempt in contrast to those in the MSIG, where only 58.4% of patients received IVT (table 2).

No statistically significant differences in stroke severity, location, stroke etiology, and logistics, such as onset-to-needle time for IVT, onset-to-groin time for MT, and in MT-failure-declaration time between the MSIG and CG1 or CG2, were identified. Insignificantly higher rates of successful thrombectomy device insertion (success in passing to the occlusion site) with a higher percentage of TICI scores of 1 were observed in the CG2 (32.0% vs 8.3% in the MSIG and 10.0% in the CG1; table 2). One patient was supplemented with Haemocomplettan due to low fibrinogen levels prior to surgery.

Eight stand-alone microsurgical embolectomies, two combined microsurgical embolectomies with EC–IC bypass procedures, and one stand-alone EC–IC bypass without M1 and M2 direct exploration were performed in the MSIG. Spontaneous MCA recanalization was observed during open vessel manipulation in one patient in the MSIG. Cases of M1 and M2 atherosclerosis were encountered regularly, even for patients in whom intracranial atherosclerosis was not evident on the preoperative CT scans (7/12 patients). Complete recanalization (TICI score of 2b–3) was achieved in nine (75.0%) MSIG subjects with MSI. Performance of the EC–IC bypass without ME automatically excluded one patient from TICI evaluation (table 3).

MSIG patients showed notably better clinical outcomes, expressed both as rapid clinical improvement at 24 hours and as mRS score on day 90 after the stroke. Favorable clinical outcome (mRS score 0–2) on day 90 was reached in 58.3% of MSIG patients compared with 10.0% of patients in the CG1 (OR=12.60; 97.5% CI 0.84 to 187.99; p=0.062) and with 12.0% in the CG2 (OR=10.27; 97.5% CI 1.53 to 68.92; p=0.012; figure 1, table 4).

sICH incidence and overall 7-day and 90-day mortality did not differ significantly between the groups (table 4).

DISCUSSION

The results of this study showed that MSI is a safe and potentially efficient method in patients with acute stroke after a failed MT procedure, offering high probability of MCA recanalization. The recanalization was achieved in 75% of patients (expressed as a TICI score of 2b–3) who underwent microsurgical intervention.

J NeuroIntervent Surg: first published as 10.1136/neurintsurg-2022-018643 on 15 April 2022. Downloaded from http://jnis.bmj.com/ on April 20, 2022 at Cambridge University Library. Protected by copyright.

Table 3 Surgery data

Surgery group, n (%)	12 (100)
Type of surgery	
Microsurgical embolectomy; n (%)	8 (66.7)
Microsurgical embolectomy +STA-MCA bypass; n (%)	2 (16.7)
Only STA-MCA bypass; n (%)	1 (8.4)
Recanalization during vessel manipulation; n (%)	1 (8.4)
Craniotomy	
Pteryonal; n (%)	6 (50.0)
Lateral supraorbital; n (%)	3 (25.0)
Minimally invasive and rapid surgical embolectomy; n (%)	2 (16.7)
Tailored craniotomy to recipient M3-branch during STA-MCA bypass	1 (8.3)
Arteriotomy during embolectomy	
Longitudinal; n (%)	7 (58.3)
Transverse; n (%)	3 (25.0)
No arteriotomy; n (%)	2 (16.7)
Vessel suture method	
Surgical suture; n (%)	6 (50.0)
Miniclip; n (%)	1 (8.4)
Suture +miniclip; n (%)	4 (33.3)
No suture; n (%)	1 (8.4)
Time data	
Onset to skin cut; mean±SD (min)	306±81.7
Onset to flow; mean±SD (min)	404.8±109.1
Flow in occluded artery after surgery	
TICI after surgery; mean±SD	2.7±0.9
TICI 0 to 1; n (%)	1 (8.4)
TICI 2a; n (%)	1 (8.4)
TICI 2b–3; n (%)	9 (75.0)

MCA, middle cerebral artery; STA, superficial temporal artery; TICI, thrombolysis in cerebral infarction.

A favorable clinical outcome on day 90 was achieved in 58.3% of interventions in patients with no sICH or other serious complication. In comparison, only 12% of patients had a favorable clinical outcome after 90 days in the control groups (OR=12.60 and OR=10.27, respectively). Owing to the low number of patients, the difference was not statistically significant in comparison with the CG1. On the contrary, the difference between the MSIG and CG2 was statistically significant. However, this was a case–control comparison.

To the best of the authors' knowledge, this is the first controlled study investigating the safety and efficacy of emergent MSI, including MSE and/or EC–IC bypass, with favorable clinical outcomes in patients with AIS with symptomatic MCA occlusion after MT and/or IVT failure.

IVT with recombinant tissue plasminogen activator at a dose of 0.9 mg/kg within 4.5 hours since the onset of AIS symptoms is the standard of care in patients fulfilling the indication criteria. Multiple trials studying ELVO have shown that MT is beneficial when performed within 6 hours after stroke onset.[21–25] Nevertheless, IVT is still recommended as a first-choice treatment followed by MT in cases of IVT failure. A time window extension for IVT

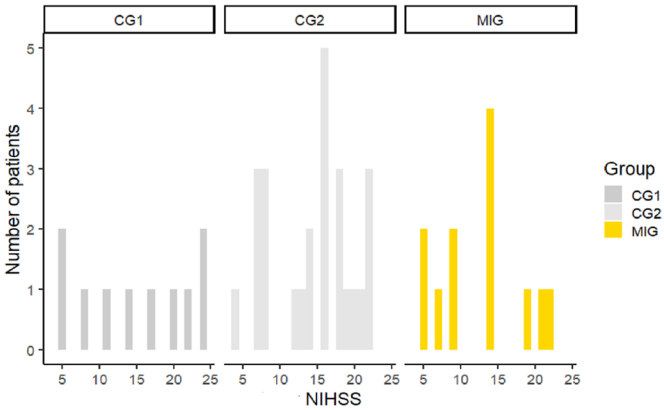

Figure 1 Microsurgical intervention increased the number of patients with a 3-month modified Rankin scale (mRS) score of 0. Distribution of the mRS score after 3 months for the microsurgical intervention group (MSIG) and for control groups 1 and 2 (CG1 and CG2, respectively) are shown.

and/or MT could be considered under specific circumstances up to 24 hours in select patients based on advanced perfusion imaging results.[16] Nevertheless, early brain artery recanalization was not achieved in a significant percentage of patients. In addition, published studies have shown that persistent ELVO predicts poor clinical outcomes.[6]

A systematic review was performed to evaluate available data on efficacy and safety of MSI in patients with AIS and ELVO and failure of combined revascularization therapy within 8, 16, and 24 hours after stroke onset. The search strategy has been previously described in the systematic review protocol.[26] Available data on this topic are limited, with no randomized clinical trials having been performed to date. Neither MSE nor EC–IC bypass is a part of current evidence-based guidelines or protocols for management of AIS with ELVO. Only cases of minimally invasive and rapid surgical embolectomy have been described in non-atherosclerotic artery occlusions,[18] similarly to cases of MSE in patients with ELVO for whom MT failed within 8 hours since the onset of symptoms with a favorable clinical outcome after MI.[27] Emergent EC–IC bypass with low hemorrhagic complication rates immediately following IVT has been rarely documented.[8] A low level of fibrinogen after IVT might be a risk factor for surgery complications. We experimentally used Haemocomplettan in one patient with fibrinogen level <1 g/L, but more studies are needed to determine the optimal therapeutic protocol. A calcified embolus of an intracranial artery found on the baseline images represents a more specific case. The recombinant tissue plasminogen activator activates plasminogen into plasmin, but plasmin will not lyse a calcified embolus. Successful endovascular removal of a calcified cerebral embolus is possible, but information on this procedure is also limited.[28 29]

Considering our study and previously published data, approximately 3–9% of patients with ELVO in the anterior circulation could benefit from microsurgical intervention after unsuccessful MT and optional rescue stenting failure (4.5% in the current study).[4 5]

Our study evaluated this subject matter relying on only one available recent randomized study in English.[30] This study demonstrated the lack of EC–IC bypass efficacy in secondary stroke prevention. Neither emergent nor urgent revascularization was studied.[30]

Conversely, the benefits of the present study should be noted as well. These include the consistent and comparable

J NeuroIntervent Surg: first published as 10.1136/neurintsurg-2022-018643 on 15 April 2022. Downloaded from http://jnis.bmj.com/ on April 20, 2022 at Cambridge University Library. Protected by copyright.

Table 4 Main study results

	MSIG (n=12)	CG1 (n-10)	P value	CG2 (n=25)	P value
NIHSS score at admission; median (IQR)	14.0 (5–22)	15.5 (5–24)	0.888*	16.0 (4–22)	0.757*
NIHSS score after 24 hours; median (IQR)	7.0 (0–21)	16.0 (2–23)	0.241*	14.0 (3–25)	0.158*
NIHSS at day 7 (alive only); median (IQR)	3.0 (0–19)	13 (2–19)	0.502*	14 (2–35)	0.110*
mRS score 0–2 prior to stroke; n (%)	12 (100.0)	9 (90.0)	0.910†	25 (100.0)	1.000
mRS score 3 prior to stroke; n (%)	0 (0.0)	1 (10.0)	0.910†	0 (0.0)	1.000
mRS score 0–1 at day 90; n (%)	6 (50.0)	1 (10.0)	0.148†	2 (8.0)	0.016†
mRS score 0–2 at day 90; n (%)	7 (58.3)	1 (10.0)	0.062†	3 (12.0)	0.012†
mRS score 0–3 at day 90; n (%)	7 (58.3)	2 (20.0)	0.198†	4 (16.0)	0.036†
mRS score 4–5 at day 90; n (%)	1 (8.3)	2 (20.0)	0.667†	15 (60.0)	0.003†
Death within 7 days; n (%)	0 (0.0)	3 (30.0)	0.156†	0 (0.0)	1.000
Death within 90 days; n (%)	4 (33.3)	6 (60.0)	0.782†	6 (24.0)	1.000†
Cerebral edema; n (%)	0 (0.0)	3 (30.0)	0.156†	4 (16.0)	0.564†
Decompressive craniectomy; n (%)	0 (0.0)	0 (0.0)	1.000†	1 (4.0)	1.000†
sICH; n (%)	0 (0.0)	0 (0.0)	1.000†	1 (4.0)	1.000†

*Mann-Whitney U-test;
†Fisher's exact test;
CG1, control group in center 1; CG2, control group in center 2; mRS, modified Rankin scale; MSIG, microsurgical intervention group; NIHSS, National Institutes of Health Stroke Scale; sICH, symptomatic intracerebral hemorrhage.

baseline and logistical findings between subject groups and the established and strictly followed study protocol with clear criteria.

Our study has some limitations. First, a relatively small number of subjects were enrolled in the study. Thus, two control groups (with random allocation and case–control) were created in order to improve the study's informative value. Nevertheless, a multicenter randomized control trial should be performed in the future to confirm the present results. Second, two different surgical methods (MSE and EC–IC bypass) and their combination were used in patients undergoing a surgical intervention. Comparison of safety and efficacy for each method was not performed owing to the smallnumber of patients in each subgroup. Third, we did not compare early postoperative CT findings. The postoperative CT findings are usually affected by the egress of the cerebrospinal fluid during surgery. Moreover, artifacts from potential clipping during microsurgical intervention can distort the imaging. Thus, both visual and digital image analysis evaluations could be biased. Finally, an evaluation of neurological status and clinical outcome was not performed by a neurologist blinded to the experimental conditions. Nevertheless, all neurologists were trained in NIHSS and mRS evaluations. There are still experienced open cerebrovascular neurosurgeons in tertiary centers who can perform traditional microsurgery. As a salvaging procedure for patients with penumbral tissue remaining after failed endovascular stroke, microsurgical interventions should be systematically evaluated.

CONCLUSIONS

The results of this prospective two-center cohort study showed that microsurgical intervention represents a safe and potentially effective treatment method for a small subgroup of patients with AIS with MCA occlusion and MT failure. Microsurgery should be tested in randomized control trials as a third-tier option in patients with ELVO.

Author affiliations
[1]Department of Neurosurgery, Nemocnice České Budějovice, České Budějovice, Jihočeský, Czech Republic
[2]Department of Neurosurgery, Univerzita Karlova Lékařská fakulta v Plzni, Plzeň, Plzeňský, Czech Republic
[3]Department of Neurology, University Hospital Ostrava, Ostrava, Moravskoslezský, Czech Republic
[4]Center for Health Research, Faculty of Medicine, University of Ostrava, Ostrava, Moravskoslezský, Czech Republic
[5]Department of Neurology, Nemocnice České Budějovice, České Budějovice, Jihočeský, Czech Republic
[6]Department of Neurosurgery and Neurooncology, First Faculty of Medicine, Charles University and Military University Hospital, Praha, Praha, Czech Republic
[7]Department of Radiology, University Hospital Ostrava, Ostrava, Moravskoslezský, Czech Republic
[8]Department of Biophysics, Faculty of Medicine and Dentistry, Palacký University Olomouc, Olomouc, Olomoucký, Czech Republic

Collaborators EMIAS Study Group: Miroslava Nevšímalová, Martin Reiser (Department of Neurology, České Budějovice Hospital, České Budějovice, Czech Republic), Jindřich Sova, Karel Hes, Petr Mašek (Department of Radiology, České Budějovice Hospital, České Budějovice, Czech Republic), Martin Bombic (Department of Neurosurgery, České Budějovice Hospital, České Budějovice, Czech Republic), Eva Hurtíková (Department of Neurology, University Hospital Ostrava, Ostrava, Czech Republic) Jan Krajča, Tomáš Jonszta, Daniel Czerný (Department of Radiology, University Hospital Ostrava, Ostrava, Czech Republic)

Contributors JF made a substantial contribution to the concept and design, analysis and interpretation of data; drafted the article; approved the version to be published. He is a guarantor. MR made a substantial contribution to the concept and design, analysis and interpretation of data; drafted the article; approved the version to be published. MG, SO, and VP revised the article critically for important intellectual content; approved the version to be published. KL made a substantial contribution to the study design, analysis and interpretation of data; revised the article critically for important intellectual content; approved the version to be published. DŠ made a substantial contribution to the concept and design, acquisition of data; approved the version to be published.

Funding This work was supported by the Ministry of Health of the Czech Republic grants number NV-19-04-00270, NU22-04-00389, and Palacký University grant number JG_2019_004.

Competing interests None declared.

Patient consent for publication Not applicable.

Ethics approval This study involves human participants and was approved by the

J NeuroIntervent Surg: first published as 10.1136/neurintsurg-2022-018643 on 15 April 2022. Downloaded from http://jnis.bmj.com/ on April 20, 2022 at Cambridge University Library. Protected by copyright.

ethical committee of the České Budjovice Hospital. ID No. 109/17 . Participants gave informed consent to participate in the study before taking part.

Provenance and peer review Not commissioned; externally peer reviewed.

Data availability statement Data are available in a public, open access repository. Dataset is available: Školoudík, David (2021), "EMIAS Study", Mendeley Data, V1, doi: 10.17632/ptmn436pzm.1.

Supplemental material This content has been supplied by the author(s). It has not been vetted by BMJ Publishing Group Limited (BMJ) and may not have been peer-reviewed. Any opinions or recommendations discussed are solely those of the author(s) and are not endorsed by BMJ. BMJ disclaims all liability and responsibility arising from any reliance placed on the content. Where the content includes any translated material, BMJ does not warrant the accuracy and reliability of the translations (including but not limited to local regulations, clinical guidelines, terminology, drug names and drug dosages), and is not responsible for any error and/or omissions arising from translation and adaptation or otherwise.

ORCID iDs
Jiří Fiedler http://orcid.org/0000-0001-7886-6021
Martin Roubec http://orcid.org/0000-0002-4915-4284
Svatopluk Ostrý http://orcid.org/0000-0003-1858-7922
Václav Procházka http://orcid.org/0000-0002-2410-2314
David Školoudík http://orcid.org/0000-0002-2651-3424

REFERENCES

1 Wahlgren N, Moreira T, Michel P, *et al*. Mechanical thrombectomy in acute ischemic stroke: consensus statement by ESO-Karolinska stroke update 2014/2015, supported by ESO, ESMINT, ESNR and EAN. *Int J Stroke* 2016;11:134–47.
2 Leischner H, Flottmann F, Hanning U, *et al*. Reasons for failed endovascular recanalization attempts in stroke patients. *J Neurointerv Surg* 2019;11:439–42.
3 Roubec M, Kuliha M, Procházka V, *et al*. A controlled trial of revascularization in acute stroke. *Radiology* 2013;266:871–8.
4 Dobrocky T, Kaesmacher J, Bellwald S, *et al*. Stent-retriever thrombectomy and rescue treatment of M1 occlusions due to underlying intracranial atherosclerotic stenosis: cohort analysis and review of the literature. *Cardiovasc Intervent Radiol* 2019;42:863–72.
5 Maingard J, Phan K, Lamanna A, *et al*. Rescue intracranial stenting after failed mechanical thrombectomy for acute ischemic stroke: a systematic review and meta-analysis. *World Neurosurg* 2019;132:e235–45.
6 Rajajee V, Kidwell C, Starkman S, *et al*. Early MRI and outcomes of untreated patients with mild or improving ischemic stroke. *Neurology* 2006;67:980–4.
7 Horiuchi T, Nitta J, Ogiwara T, *et al*. Outcome predictors of open embolectomy in middle cerebral artery occlusion. *Neurol Res* 2009;31:892–4.
8 Kanematsu R, Kimura T, Ichikawa Y, *et al*. Safety of urgent STA-MCA anastomosis after intravenous rt-PA treatment: a report of five cases and literature review. *Acta Neurochir* 2018;160:1721–7.
9 Yaşargil MG. Personal considerations on the history of microneurosurgery. *J Neurosurg* 2010;112:1163–75.
10 Hino A, Oka H, Hashimoto Y, *et al*. Direct microsurgical embolectomy for acute occlusion of the internal carotid artery and middle cerebral artery. *World Neurosurg* 2016;88:243–51.
11 Inoue T, Tamura A, Tsutsumi K, *et al*. Surgical embolectomy for large vessel occlusion of anterior circulation. *Br J Neurosurg* 2013;27:783–90.
12 Powers WJ, Rabinstein AA, Ackerson T, *et al*. 2018 guidelines for the early management of patients with acute ischemic stroke: a guideline for healthcare professionals from the American Heart Association/American Stroke Association. *Stroke* 2018;49:e46–110.
13 Powers WJ, Rabinstein AA, Ackerson T, *et al*. Guidelines for the early management of patients with acute ischemic stroke: 2019 update to the 2018 guidelines for the early management of acute ischemic stroke: a guideline for healthcare professionals from the American Heart Association/American Stroke Association. *Stroke* 2019;50:e344–418.
14 Wahlgren N, Ahmed N, Dávalos A, *et al*. Thrombolysis with alteplase for acute ischaemic stroke in the Safe Implementation of Thrombolysis in Stroke-Monitoring study (SITS-MOST): an observational study. *Lancet* 2007;369:275–82.
15 Turc G, Bhogal P, Fischer U, *et al*. European Stroke Organisation (ESO) - European Society for Minimally Invasive Neurological Therapy (ESMINT) guidelines on mechanical thrombectomy in acute ischaemic stroke endorsed by Stroke Alliance for Europe (SAFE). *Eur Stroke J* 2019;4:6–12.
16 Berge E, Whiteley W, Audebert H, *et al*. European Stroke Organisation (ESO) guidelines on intravenous thrombolysis for acute ischaemic stroke. *Eur Stroke J* 2021;6:I–LXII.
17 Higashida RT, Furlan AJ, Roberts H. Technology assessment committee of the American Society of Interventional and Therapeutic Neuroradiology; technology assessment committee of the Society of Interventional Radiology. Trial design and reporting standards for intra-arterial cerebral thrombolysis for acute ischemic stroke. *Stroke* 2003;34:e109–37.
18 Park J, Hwang Y-H, Huh S, *et al*. Minimally invasive and rapid surgical embolectomy (MIRSE) as rescue treatment following failed endovascular recanalization for acute ischemic stroke. *Acta Neurochir* 2014;156:2041–9.
19 Sugiyama T, Kazumata K, Asaoka K, *et al*. Reappraisal of microsurgical revascularization for anterior circulation ischemia in patients with progressive stroke. *World Neurosurg* 2015;84:1579–88.
20 Trouillas P, Derex L, Philippeau F, *et al*. Early fibrinogen degradation coagulopathy is predictive of parenchymal hematomas in cerebral rt-PA thrombolysis: a study of 157 cases. *Stroke* 2004;35:1323–8.
21 Campbell BCV, Mitchell PJ, Kleinig TJ, *et al*. Endovascular therapy for ischemic stroke with perfusion-imaging selection. *N Engl J Med* 2015;372:1009–18.
22 Jovin TG, Chamorro A, Cobo E, *et al*. Thrombectomy within 8 hours after symptom onset in ischemic stroke. *N Engl J Med* 2015;372:2296–306.
23 Goyal M, Menon BK, van Zwam WH, *et al*. Endovascular thrombectomy after large-vessel ischaemic stroke: a meta-analysis of individual patient data from five randomised trials. *Lancet* 2016;387:1723–31.
24 Berkhemer OA, Fransen PSS, Beumer D, *et al*. A randomized trial of intraarterial treatment for acute ischemic stroke. *N Engl J Med* 2015;372:11–20.
25 Saver JL, Goyal M, van der Lugt A, *et al*. Time to treatment with endovascular thrombectomy and outcomes from ischemic stroke: a meta-analysis. *JAMA* 2016;316:1279–88.
26 Klugar M, Fiedler J, Líčeník R, *et al*. Efficacy and safety of emergent microsurgical embolectomy in patients with acute ischemic stroke after the failure of intravenous thrombolysis and mechanical thrombectomy – a systematic review protocol. *Cesk Slov Neurol N* 2020;83/116:416–20.
27 Kim D-W, Jang S-J, Kang S-D. Emergency microsurgical embolectomy for the treatment of acute intracranial artery occlusion: report of two cases. *J Clin Neurol* 2011;7:159–63.
28 Fiedler J, Ostry S, Bombic M, *et al*. Urgent middle cerebral artery embolectomy of calcified embolus after intravenous thrombolysis: 2-dimensional operative video. *Oper Neurosurg* 2019;17:E54–5.
29 Ramírez-Moreno JM, Trinidad-Ruiz M, Ceberino D, *et al*. Mechanical thrombectomy during ischaemic stroke due to a calcified cerebral embolism. *Neurologia* 2017;32:270–3.
30 Powers WJ, Clarke WR, Grubb RL, *et al*. Extracranial-Intracranial bypass surgery for stroke prevention in hemodynamic cerebral ischemia: the carotid occlusion surgery study randomized trial. *JAMA* 2011;306:1983–92.

J NeuroIntervent Surg: first published as 10.1136/neurintsurg-2022-018643 on 15 April 2022. Downloaded from http://jnis.bmj.com/ on April 20, 2022 at Cambridge University Library. Protected by copyright.